

TRICKS OF THE TRADE



In *Retina Today's* 5Q column, found on the final page of each issue, we often ask retina surgeons what drew them to the specialty. Read enough of those interviews and a pattern emerges. Synonyms for *elegance* appear. The word *puzzle* is used. Passionate phrases such as *fell in love with* and *was mesmerized by* emerge in drafts.

We understand where they're coming from: there's a romance to surgery. A marriage of engineering, medical science, and talent converge in the OR and buttress each other. New tools allow gifted surgeons to become more precise with their movements. Advances in anatomic understanding fuel the need for better equipment. Superior training in fellowship motivates surgeons to collaborate with industry to craft more advanced instruments.

This issue of *Retina Today* explores how our field thinks about surgery, both inside and outside the OR.

Michael A. Klufas, MD, highlights some of the latest videos on Eyetube, the online depot of surgical videos that even the best surgeons use to keep track of the field's trends. Ashley M. Crane, MD; and David A. Eichenbaum, MD, share pearls for Dutch Ophthalmic's EVA surgical platform, shedding light on how this growing technology has improved their OR. In a review of their favorite tools, Peter A. Karth, MD, MBA; and Rahul K. Reddy, MD, MHS, review Alcon's HyperVit Dual Blade Vitrectomy Probe and Bausch + Lomb's Bi-Blade Cutter, respectively.

As retina surgeons, we're often managing cases that

involve IOLs. John W. Kitchens, MD, shares a technique for removing dropped IOLs that minimizes the risk of creating iatrogenic injury. Second-year Wills Eye Hospital fellows Thomas L. Jenkins, MD; Ravi R. Pandit, MD, MPH; and David Xu, MD, provide an introduction to secondary IOLs that is a great place to start for anyone who needs a survey of the latest technology.

Some of the topics in this issue take place outside of the OR. Ragui W. Sedeek, MD, makes the case for why laser therapy ought to play a large role in the management of patients with diabetic eye disease. Michael C. Renfroe, BSA; Gowtham Jonna, MD; Yong Ren, MMS; Saradha Chexal, MD; and Chirag D. Jhaveri, MD, explore how use of OCT angiography could affect the duration of facedown positioning for patients who underwent macular hole surgery.

And what about avoiding the OR altogether? Madeleine Webb, BA, BS; and Brian C. Joondeph, MD, MPS, profile a case in which surgery for a macular hole was obviated by a course of topical NSAID drops. By relying on outside-the-box thinking, the risks of surgery were avoided.

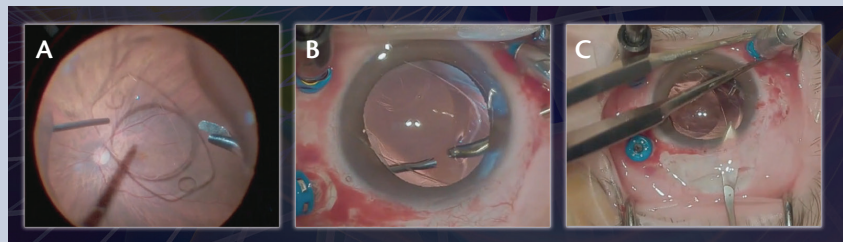
This issue is our gift to retina surgeons. We hope you find it useful. ■

CHIEF MEDICAL EDITOR

ASSOCIATE MEDICAL EDITOR

From the Cover

John W. Kitchens, MD, wrote an article in this issue about a technique for removing dropped plate haptic IOLs. By using a soft-tip cannula for removal of the IOL, he mitigates the risk of iatrogenic injury (A). Dr. Kitchens describes moving the IOL to the middle of the vitreous cavity, where safe manipulation is possible (B). The large incision required to remove the IOL doubles as an entry point for an anterior chamber IOL or other large IOL (C).



Want to know how Donald J. D'Amico, MD; María H. Berrocal, MD; and Timothy G. Murray, MD, MBA, reacted to the technique shared by Dr. Kitchens? Read his article in this issue's cover focus to find out.